

The Proper Diagnostic Pathway of Gardner's Syndrome: Role of the Dentist in the Early Detection of the Associated Systemic Pathologies

Francesco Inchingolo¹, Andrea Pacifici², Marco Gargari³, Massimo Marrelli⁴, Angelo M Inchingolo⁵, Gianna Dipalma⁵, Alessio D Inchingolo⁵, Raffaele Cagiano⁶, Luigi Santacroce⁷, Francesco W Guglielmi⁸, Luca Signorini^{9*}, Luciano Pacifici^{2*}, Marco Tatullo^{10*}

¹Department of Interdisciplinary Medicine, General Hospital, Bari, Italy. ²Department of Stomatology and Maxillofacial Sciences, University of Rome "Sapienza", Rome, Italy. ³Department of Clinical Sciences and Translational Medicine, University of Rome "Tor Vergata", Rome, Italy. ⁴Maxillofacial Surgery Unit, Calabrodental clinic, Crotona, Italy. ⁵Private Practice, St. Melo da Bari, Bari, Italy. ⁶Department of Biomedical Sciences and Human Oncology, Medical Faculty, University of Bari "Aldo Moro", Italy. ⁷University of Bari; JSGEM Department - Section of Taranto, Italy. ⁸Section of Gastroenterology & Artificial Nutrition, "San Nicola Pellegrino" Hospital Trani, (Ba), Italy. ⁹Private Practice, St. Regina Margherita, Rome, Italy. ¹⁰Tecnologica Research Institute, Biomedical Section, Crotona, Italy.

*These Authors equally contributed to this research

Abstract

Gardner's syndrome is a genetic disease which leads to a high chance of malignant degeneration in untreated patients. Typically, it presents intestinal polyposis, bone and mesenchymal tumors. The initial symptoms often appear in the head-neck area with osteomas, several dental anomalies, odontogenic tumors, exostosis and epidermoid cysts. In this sense, the role of odontologists and maxillofacial surgeons is of crucial importance in the early diagnosis of this syndrome, which is potentially fatal.

A young female patient came to our attention with a slight swelling at the level of the right mandibular angle and a limitation of the mandibular movements. Dental panoramic showed atypical presence of deciduous teeth and an inflammation of dental sac surrounding the 4.8 tooth. Anamnesis revealed a family history of colon cancer. She referred irregular bowels, with occasional blood loss into the feces. Based on these informations, we hypothesize the diagnosis of Gardner's syndrome. On our recommendation, the patient performed colon endoscopic examination, which showed the presence of multiple polyps, and a genetic screening of APC gene in the 5q21 locus, which confirmed our diagnostic hypothesis. Dental management was performed with 4.8 extractions and a complete orthodontic treatment. Gardner's syndrome is a genetic disease which high incidence of malignant degeneration.

The importance of an early diagnosis, even in all those cases where the typical clinical frameworks are missing, as in this case report, lies in the possible lethal outcome of this disorder, if not treated in the early stages. These examinations could save the patient's life.

Key Words: Gardner's Syndrome, Gastrointestinal polyposis, Oral oncology

Introduction

Gardner's syndrome, a variant of Familial Adenomatous Polyposis (FAP), is a genetic disorder with highly penetrant autosomal-dominant transmission (80-100%). The incidence of FAP is approximately 1:7500 births [1,2], while Gardner's syndrome occurs in 1:14000 births [1,3]. The first researcher reporting a clinical case characterized by the presence of manifestations which could be ascribed to Gardner's syndrome was Fitzgerald in 1943 [4-6], however, the combination of these signs was recognized as a genetically determined syndrome only in 1953 by Gardner e Richards [4,7,8]. This disease is characterized by the following triad: Gastrointestinal polyposis, with a 100 percent chance of malignant degeneration [1,9-12]; other signs are bone tumors, frequently located on maxillary and cranial bones, and lastly the soft tissues tumors. Other extra-intestinal manifestations include retinal lesions, dental anomalies and other malignant neoplasms.

Gardner's syndrome should enter in differential diagnosis with odontogenic tumors, Cowden syndrome and Peutz-Jeghers syndrome. The importance of an early diagnosis lies in the high malignant potential of this syndrome. In this light, the dentists and the maxillofacial surgeons should be able to

recognize the signs of this syndrome, which frequently occurs in the head-neck region and are often the alarm bell of this unrecognized disease.

Aim of this report is to show how a careful dental examination and a proper medical anamnesis are the way to early diagnosis of Gardner's Syndrome: The correct clinical diagnosis could lead to further tests in order to verify other most pathogenic aspects related to this syndrome.

Case report

A 23 year old female patient reported pain in the right mandibular molar region. The extraoral examination showed the presence of a slight swelling at the level of the right mandibular angle and a reduction of the mandibular movements. The intraoral examination revealed the persistence in the dental arches of two deciduous teeth, with some permanent elements retained; furthermore, enamel hypoplasia in all the teeth was clinically observed. X-rays panoramic showed the presence of impacted third molars, and in the intraosseous area close to the molar 48, it was evident a radiolucent zone which suggested an inflammatory process of periodontal sac, with a probable bacterial infection that would justify the mandibular edema, as reported by the patient (*Figure 1*).

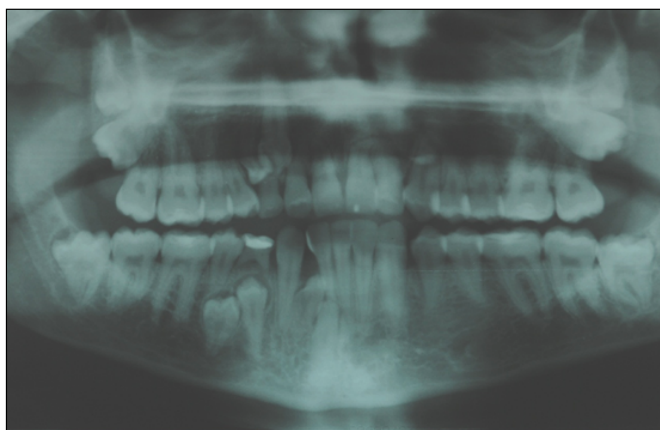


Figure 1. The X-Ray O.P.T. shows the presence of multiple impactions and supernumerary teeth.

During general anamnesis, the patient referred irregular bowels, with occasional blood loss in feces; further informations highlighted that her father had a total colectomy and her paternal grandfather died of colorectal carcinoma.

On the basis of the clinical data and the family medical history, we hypothesize the diagnosis of Gardner's syndrome.

On our recommendation, the patient performed endoscopic examination of colon, which showed the presence of multiple polyps (*Figure 2*), spread on the whole length of the colon. Histological investigations of polyps tissue revealed they were tubule-villous adenomas. The gastroenterologists advised the patient to undergo colectomy. It was decided to perform a genetic screening: this examination revealed an alteration in the 5q21 locus of the APC gene, which confirmed our diagnostic hypothesis. The patient was suggested to have regular specialist examinations.

In relation to the dental treatment, we have opted for the extraction of 48 (*Figure 3*), followed by antibiotic therapy. Subsequently, the residuals deciduous teeth were extracted, and orthodontic treatment was planned to reposition in the dental arch her teeth not yet erupted. Patient is still under periodical follow-up.

Discussion

Gardner's syndrome is a genetic disease presenting high incidence of malignant degeneration [1,13]. Spontaneous mutations of the APC gene (adenomatous polyposis coli), which is located on the long arm of chromosome 5q21-q22 [4,14], represent the genetic predisposition toward the development of colorectal carcinoma, according to Volgestein researches [15].

Gardner's syndrome has been usually associated with a triad of symptoms: Polyposis of the gastrointestinal tract, bone tumors and soft tissue tumors (desmoid tumors and epidermoid cysts). It also includes other extra intestinal manifestations, such as retinal lesions, dental anomalies and other malignant neoplasms.

The first symptoms of colorectal involvement are usually diarrhea, rectal bleeding and mucus discharge, similarly to what has been reported in this report. The treatment is surgical and involves colectomy [1,16]. The extra intestinal manifestations can occur many years before the onset of the intestinal polyps, which are often pauci symptomatic [9]. Therefore dentists, radiologists and internists should be aware

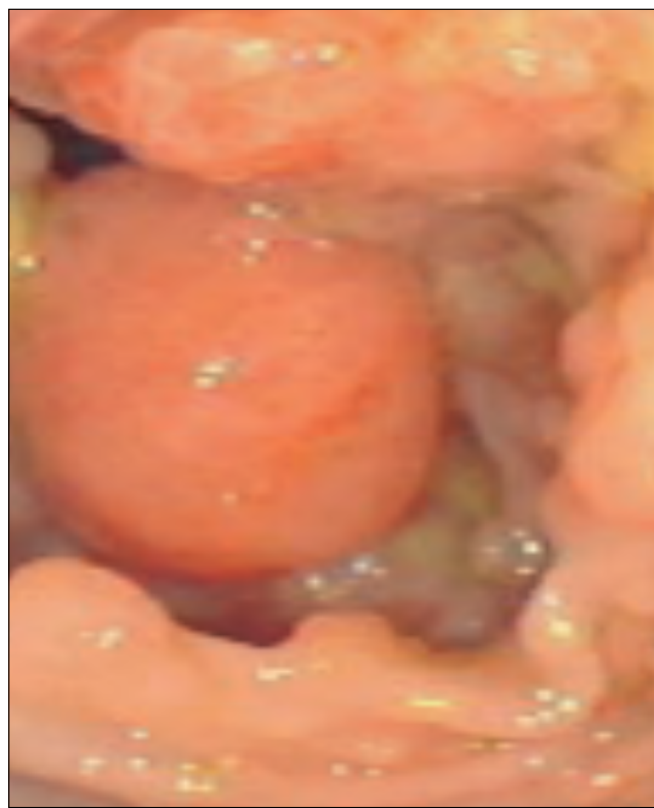


Figure 2. Colon endoscopic examination shows the presence of multiple polyps.

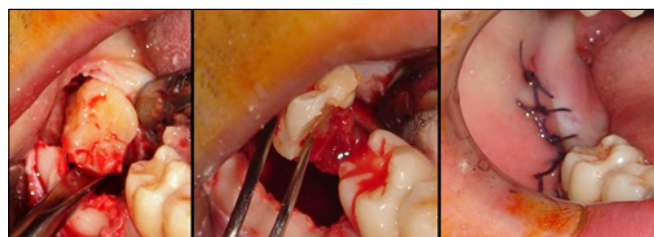

Figure 3. Surgical extraction of lower right third molar 48.

of the manifestations of this disease, in order to identify it earlier and to start with the proper follow-up of patients at risk.

Osteomas are benign bone tumors which occur more commonly on the cranial vault (especially on frontal and occipital bone), and on the maxillary bones, especially the mandible. In the latter, the most affected areas are the lingual side of the body, the angle, the lower edge and the condylar region, causing facial asymmetry [4,17]. They can also affect the maxillary and frontal sinuses. They manifest in 62-80% of patients with Gardner's syndrome and the average number of osteomas varies between 2,9 and 5,9 [4,18]. They can reach a considerable size (over 3cm). The presence of multiple areas of bone thickening represents an alarm bell which should lead the clinician to take a thorough family medical history, and perform the appropriate radiological follow-up and genetic screening for the APC gene [19]. The treatment recommended for this disease is the surgical excision of osteomas of considerable size, responsible for functional or esthetic problems.

Other neoplasms that occur with a higher incidence, compared to the general population, are thyroid carcinoma, suprarenal carcinoma, biliary pancreatic adenoma, hepatoblastoma and malignant tumors of the central nervous system [20]. The papilliferous adenocarcinoma of the thyroid

tends to be multicentric and can precede the identification of colon polyps or occur after colectomy. Owing to the high incidence of metastasis and mortality, it becomes important a thorough diagnostic screening at regular intervals, comprising neck palpation, ultrasound scan and, if necessary, a fine-needle aspiration biopsy (FNAB) [10].

Patients with Gardner's syndrome show orofacial anomalies in about 75% of cases: The most frequent clinical sign are the osteomas which are present in 30-75% of syndromic patients. Osteomas can affect both the maxillary bones, as well as other cranial bones [21].

The most frequent dental anomalies include supernumerary teeth, multiple dental impactions, dental agenesis, fused roots, malpositions and malformations; resorption of roots adjacent to a supernumerary may occur but it is extremely rare [22].

In addition to this, it is possible to find odontogenic tumors, dentigerous cysts, multiple caries [10,11]. Dental anomalies have a higher incidence in patients affected by Gardner's syndrome compared to the general population: In a recent study, dental impactions were found in 11 (37,9%) out of the 29 patients affected by Gardner's syndrome [23]. A study by Chattopadhyay and Mahesh Chander showed patients that reported facial asymmetry, with a severe limitation of mouth opening and difficulty in speech because of intraoral location of tumors [24].

References

- Dorman CA "The Role of the ET Nurse in Managing Gardner's Syndrome." *Journal of Wound Ostomy & Continence Nursing*. 1996; **23**: 73-79.
- Rodrigues-Bigas MA, Mahoney MC, Karakousis CP, Petrelli MJ. "Desmoid tumors in patients with familial adenomatous polyposis." *Cancer*. 1994; **74**: 1270-1274.
- Lipkin M, Friedman E, Newmark H, Winawer SJ, Herrera L (Editors). "Identification of increased susceptibility to familial polyposis and other proposed application to studies of cancer prevention in human subjects." *Familial adenomatous polyposis*. New York: Alan R Liss. 1990.
- Timuc, in Baykul, Nurettin Heybeli, Orhan Oyar, Harun Dogru. "Multiple huge osteomas of the mandible causing disfigurement related with Gardner's syndrome: Case report." *Auris Nasus Larynx*. 2003; **30**: 447-451.
- Fitzgerald GM. "Multiple composite odontomas coinciding with other tumorous conditions." *Journal of American Dental Association*. 1943; **30**: 1408-1417.
- Jones K, Korzcak P. "The diagnostic significance and management of Gardner's syndrome." *British Journal of Oral Maxillofacial Surgery*. 1990; **28**: 80-84.
- Gardner EJ, Richards RC. "Multiple cutaneous and subcutaneous lesions occurring simultaneously with hereditary polyposis and osteomatosis." *The American Journal of Human Genetics*. 1953; **5**: 139-147.
- Thomas J, Smith H. "Gardner's syndrome. Report of a case." *Oral Surgery Oral Medicine Oral Pathology*. 1981; **51**: 213-214.
- Amit K, Trehan MD, Harold Osborn MD, Salil K. Trehan MD, Om Aggatwal MD. "Gardner's Syndrome: A case report." *The Journal of Emergency Medicine*. 1995; **13**: 489-492.
- Harned RK, Buck JL, Olmsted WW, Moser RP, Ros PR. "Extracolonic manifestations of the familial adenomatous polyposis syndromes." *American Journal of Roentgenology*. 1991; **156**: 481-485.
- Halling F, Merten HA, Lepsien G, Honig JF. "Clinical and radiological findings in Gardner's syndrome: A case report and follow-up study." *Dentomaxillofacial Radiology*. 1992; **21**: 93-98.
- Jagelman DG. "Familial adenomatous polyposis." *Progressions*. 1990; **2**: 10-16.
- Watne AL, Sohrabi A, Herrera L (Editors). "Criteria for diagnosis of inherited colonic polyposis syndromes". "Familial adenomatous polyposis." New York: Alan R Liss. 1990.
- Ballhausen WG. "Genetic testing for familial adenomatous polyposis." *Annals of the New York Academy of Sciences*. 2000; **910**: 47-49.
- Volgstein B, Fearon ER, Kern SE. "Allelotype of colorectal carcinomas." *Science*. 1989; **244**: 207.
- Herman LL, Kurlz RC, Brennan MF, Shike M. "Acute pancreatitis from intussusception of a gastric polyp in a patient with Gardner's syndrome." *Digestive Diseases and Sciences*. 1992; **37**: 955-960.
- Noren G, Roche W. "Huge osteoma of the mandible: Case report." *Journal of Oral Surgery*. 1978; **36**: 375-379.
- Katou F, Motegi K, Baba S. "Mandibular lesions in patients with adenomatosis coli." *Journal of Cranio-Maxillo Facial Surgery*. 1989; **17**: 354-358.
- Jian-Qiu Sheng, Wei-Jia Cui, Lei Fu, Peng Jin, Ying Han, Shu-Jun Li, Ru-Ying Fan, Ai-Qin Li, Ming-Zhi Zhang, Shi-Rong Li. APC gene mutations in Chinese familial adenomatous polyposis patients. *World Journal of Gastroenterology*. 2010; **16**: 1522-1526. Published online 2010 March 28. doi: 10.3748/wjg.v16.i12.1522.
- Carl W, Sullivan MA, Herrera L (Editors). "Dental abnormalities and bone lesions in patients with familial adenomatous polyposis. "Familial adenomatous polyposis." New York: Alan R Liss. 1990.
- Utsunomiya J, Nakamura T. "The occult osteomatous changes in the mandible in patients with familial polyposis coli". *British Journal of Surgery*. 1975; **62**: 45-51.
- Ramos R, Carrel A, Herrera L (Editors). "Current treatment of desmoids in familial adenomatous polyposis patients". *Familial adenomatous polyposis*. New York: Alan R Liss, 1990.
- Dawlatly EE, Al-Qurain AA, Salih-Mahmut M. "Gardner's syndrome presenting with a giant osteoma." *Annals of Saudi Medicine*. 1997; **17**: 542-544.

Conclusions

With the described analysis, the Authors want to stress the importance of an adequate knowledge of the common manifestations of Gardner's syndrome, particularly in the head-neck area, that dentist and maxillofacial surgeon must have. The importance of an early diagnosis, even in all those atypical cases, such as reported in this case report, lies in the potential fatal outcome of some clinical conditions related to Gardner's syndrome. The involvement of the head-neck region often represents the first clinical manifestation of Gardner's syndrome and, therefore, it is the duty of the dentist to orient the patient towards an adequate diagnostic course, comprising a detailed family medical history, an appropriate radiological follow-up with radiographic examinations of maxillary bones, cranium and intestinal tract by means of a clysm. Finally, genetic screenings for the mutation of APC gene and, lastly, a biopsy and histological examination of the intestinal polyps could save the patient's life.

Conflict of Interest

The authors declare that they have no competing interests.

24. Chattopadhyay CP, Chander MG. "Peripheral osteoma of the maxillofacial region diagnosis and management: A study of 06 cases." *Journal of Maxillofacial and Oral Surgery*. 2012; **11**: 425-459. doi: 10.1007/s12663-011-0223-z.

25. Yuasa K, Yonetsu K, Kanda S. "Computed tomography of the jaws in familial adenomatosis coli." *Oral Surgery Oral Medicine Oral Pathology*. 1993; **76**: 251-255.